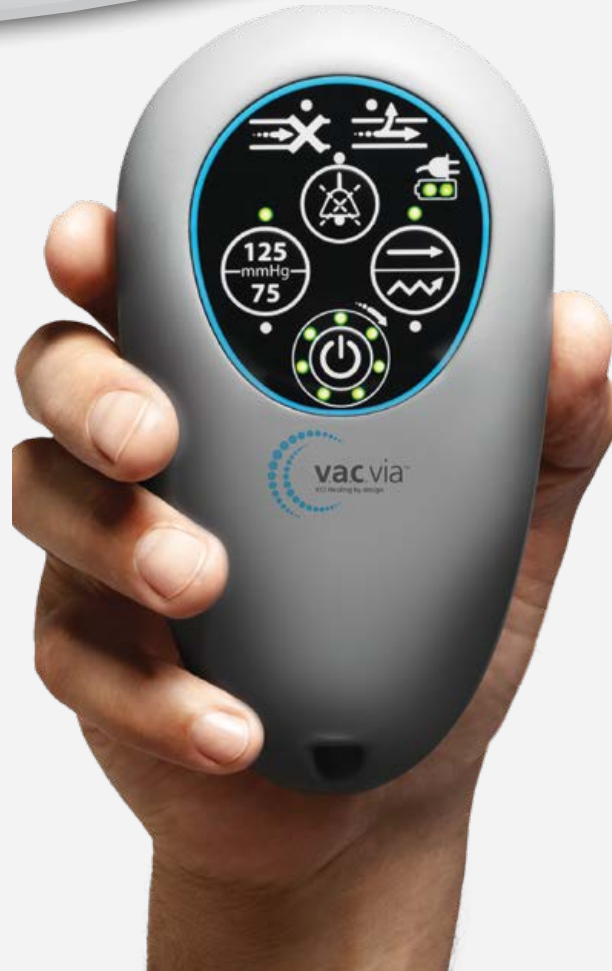



V.A.C.VIA™ NEGATIVE
PRESSURE WOUND
THERAPY



V.A.C.Via™ Negative Pressure Wound Therapy Case Studies

Case Studies

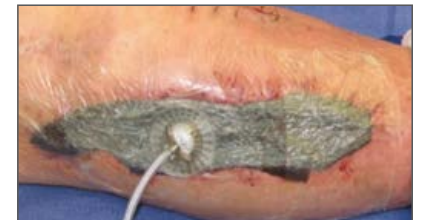Clinical experience with the V.A.C.Via™ Therapy System is reported in the following case studies.

As with any case study, the results and outcomes should not be interpreted as a guarantee or warranty of similar results. Individual results may vary depending on the patient's circumstances and condition.

Case Study 1: Dehiscence after open reduction internal fixation of tibial fracture

A 71-year-old female presented with increasing pain of the lower extremity. Patient had suffered a grade IIIB tibial fracture for which she underwent open reduction internal fixation (ORIF). She subsequently developed a polymicrobial wound infection, requiring plate replacement and multiple debridements. Patient was placed on a 6-week course of IV antibiotics for osteomyelitis. (Figure 7 A-D). Medical history included peripheral vascular disease (PVD) and type II diabetes. Following irrigation and debridement, NPWT (V.A.C. ATS® Therapy) was initiated in the wound to prepare it for STSG closure. After two days of wound bed preparation, the NPWT dressing was removed and an STSG was placed. A non-adherent layer (Adaptic® Non-adhering Dressing; Systagenix US, Quincy, MA) was cut slightly larger than the STSG and placed over the skin graft. The V.A.C.Via™ Granufoam™ Spiral dressing was trimmed to the size of the non-adherent layer and placed over it. Pressure was initiated at -125 mmHg continuously and the patient was discharged home.

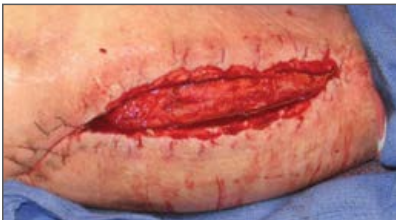On postoperative Day 6, the patient returned to the outpatient clinic and the V.A.C.Via™ Therapy dressing was removed. There was an approximately 100% graft take with good aesthetic results.



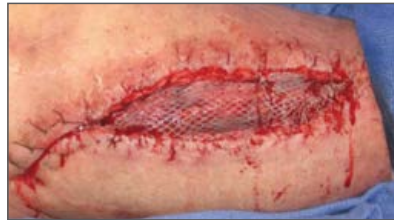C) Application of V.A.C.Via™ Therapy System over STSG

Figure 7. Case Study 1:

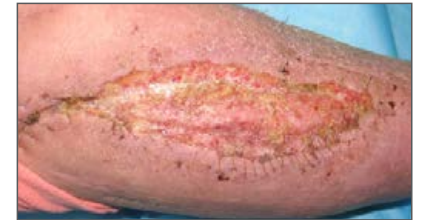Dehiscence after open reduction of tibia fracture.



A) Wound dehiscence at presentation



B) After two days of NPWT, an STSG was applied

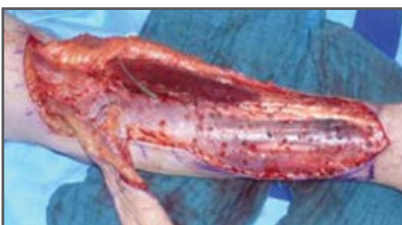

D) Wound on postoperative Day 6 after V.A.C.Via™ Therapy dressing was removed

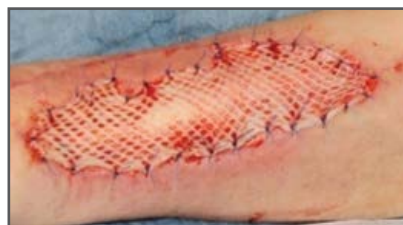Case Study 2: Free radial forearm flap transfer

A 62-year-old male patient presented with a fracture to his left leg due to a traffic accident while riding a bicycle. A free radial forearm flap transfer was used to cover the defect. Treatment of the donor site required multiple surgical interventions and subsequent meshed STSG. A V.A.C.Via™ Therapy dressing was applied at the donor site for 5 days, resulting in good healing of the STSG (Figure 8 A-C).

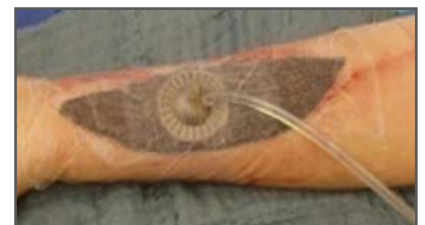Figure 8. Case Study 2:



A) Soft tissue findings after debridement before mesh-graft coverage



B) Intraoperative after mesh-graft coverage



C) V.A.C.Via™ Therapy over mesh-graft coverage

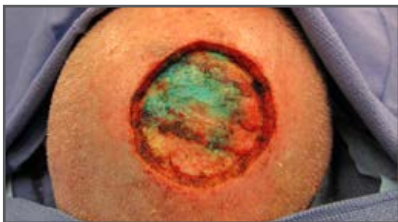
Case Study 3: Integra® Dermal Regeneration Template Placement

A 71-year-old male patient presented for evaluation of scalp reconstruction with diagnosis of melanoma Breslow thickness of 5.3mm and with a failed graft (Figure 8 A and B). Wide local excision with sentinel node biopsy was performed and bilaminar skin substitute (Integra® Dermal Regeneration Template, Integra LifeSciences, Plainsboro, NJ) was used to cover the defect (Figure 9 C-D). The patient's medical history included diabetes, PVD, and coronary artery disease. A non-adherent layer (Adaptic® Non-adhering Dressing; Systagenix US, Quincy, MA), cut slightly larger than the Integra® graft, was applied over the skin substitute. A V.A.C.Via™ Therapy dressing was applied on top of the non-adherent layer and pressure was initiated at -125 mmHg. The patient was discharged home.

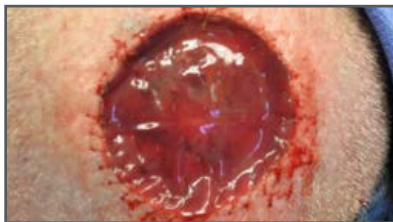On postoperative Day 5, the patient returned to the outpatient clinic for follow-up and removal of the V.A.C.Via™ Therapy dressing. The Integra® graft appeared intact and viable. Following availability of final pathology revealing clear margins, an STSG was placed on post operative Day 24. A non-adherent layer and V.A.C.Via™ Dressing were placed over the STSG. V.A.C.Via™ Therapy was discontinued 6 days post STSG with 100% take of graft reported.

In both instances, patient was discharged home with V.A.C.Via™ Therapy. Procedures were performed as outpatient and no delays for V.A.C.® Therapy approvals were encountered.

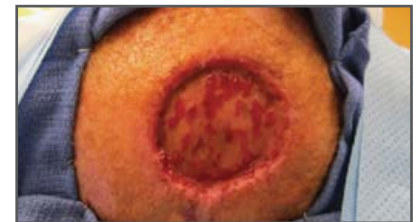Figure 9. Case Study 3:



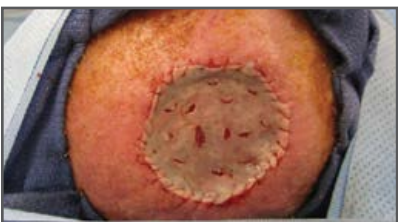A) Excision of Integra® graft



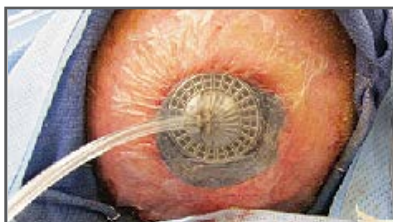B) Application of new Integra® graft



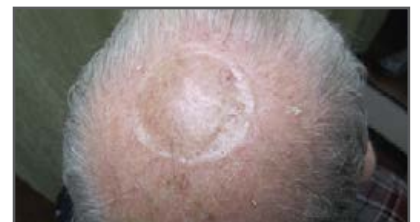C) Postoperative Day 24 after application of V.A.C.Via™ Therapy System over Integra® and before STSG



D) Application of STSG on postoperative Day 24



E) Application of NPWT over STSG



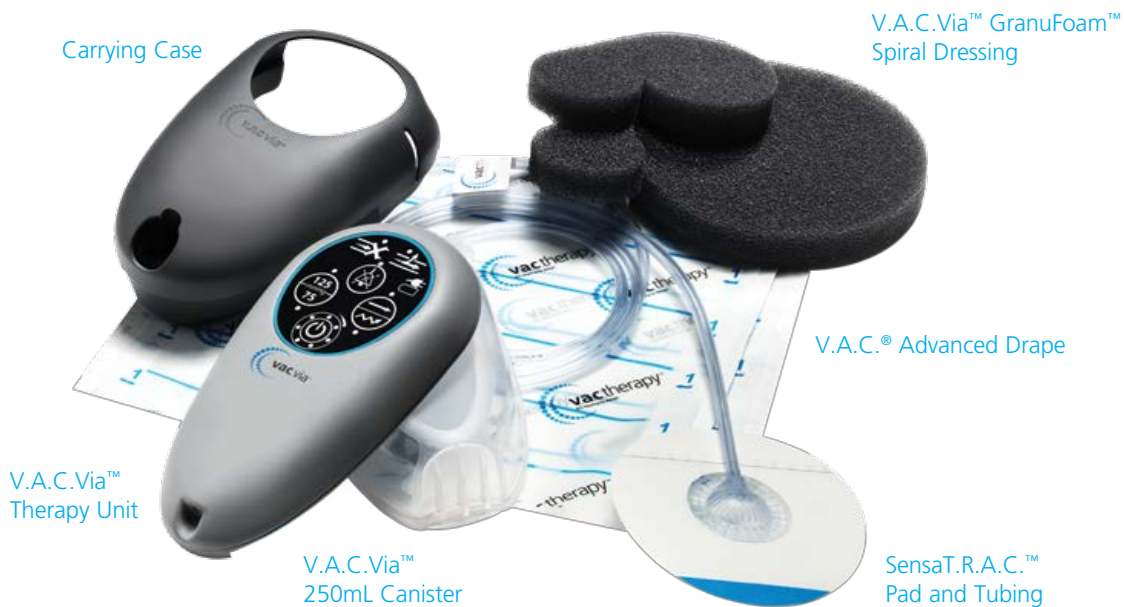F) Follow-up - 4 months Post-STSG

V.A.C.Via™ Negative Pressure Wound Therapy System

INDICATIONS FOR USE

The V.A.C.Via™ Negative Pressure Wound Therapy System is an integrated wound management system for use in acute, extended and home care settings when used on open wounds. It is intended to create an environment that promotes wound healing by secondary or tertiary (delayed primary) intention by preparing the wound bed for closure, reducing edema, promoting granulation tissue formation and perfusion, and by removing exudates and infectious materials. It is indicated for patients with chronic, acute, traumatic, sub acute and dehisced wounds, partial-thickness burns, ulcers (such as diabetic, pressure or venous insufficiency) flaps and grafts. When used on closed surgical incisions, it is intended to manage the environment of surgical incisions that continue to drain following sutured or stapled closure by maintaining a closed environment and removing exudates via the application of negative pressure wound therapy.

The V.A.C.Via™ Negative Pressure Wound Therapy System consists of the following components:



For more information about the V.A.C.Via™ Therapy System, contact your KCI Representative, visit www.kci1.com/kci1/vacvia or call **1-800-275-4524**.

Device Disposal: At the end of therapy, follow local institutional protocols for infection control and waste disposal procedures for dressings and canisters. Local protocols for the disposal of the V.A.C.Via™ device should be based on applicable federal, state and/or local government environmental regulations for recycling electronic devices.



NOTE: Specific indications, contraindications, warnings, precautions and safety information exist for the V.A.C.Via™ Therapy System. Please consult the Clinician Guide and Instructions for Use prior to application. Rx only.

©2013 KCI Licensing, Inc. All rights reserved. All trademarks designated herein are proprietary to KCI Licensing, Inc., its affiliates and/or licensors. DSL#13-0644.US (REV. 9/14)

